



# Use of Macrolane VRF 30 in Eemicumferential Penis Enlargement

Giuseppe Sito, MD; Sergio Marlino, MD; and Adriano Santorelli, MD

Aesthetic Surgery Journal  
33(2) 258–264  
© 2013 The American Society for  
Aesthetic Plastic Surgery, Inc.  
Reprints and permission:  
[http://www.sagepub.com/  
journalsPermissions.nav](http://www.sagepub.com/journalsPermissions.nav)  
DOI: 10.1177/1090820X12472337  
[www.aestheticsurgeryjournal.com](http://www.aestheticsurgeryjournal.com)



## Abstract

**Background:** Penis enlargement is increasingly in demand. Methods for penis enlargement can be classified into surgical, nonsurgical (filling), and mechanical. Each method has shown only relatively successful results. A new formulation of injectable, stabilized, hyaluronic acid (HA)–based, nonanimal gel is available that may have applications for this use.

**Objectives:** The authors propose a new technique for emicircumferential-injection filling of the penis and assess the safety and efficacy of this procedure compared with lipofilling.

**Methods:** The authors retrospectively reviewed the charts of 83 patients who underwent penis enlargement with either their HA-injection technique or lipofilling between December 2007 and July 2011. Safety, efficacy, and patient satisfaction were assessed.

**Results:** The circumferential enlargement obtained from both techniques ranged from 3.2 to 4.5 cm, with a decrement during erection. In all patients, the increase in penis length ranged from 1.8 to 3.6 cm. No complications were seen in patients treated with HA, whereas 8 patients treated with lipofilling developed granuloma, and another experienced fat necrosis. The vast majority ( $n = 72$ ) of patients reported being “very satisfied” with the results.

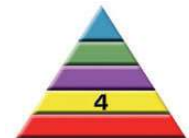**Conclusions:** The ideal technique for penis enlargement should be nonsurgical, with a satisfactory and predictable result, a low rate of complications, and long-term stability. Eemicumferential enlargement with HA filler meets these requirements. However, results have been durable but not definitive, and repeated treatment (with associated costs) is necessary.

## Level of Evidence: 4

## Keywords

hyaluronic acid, filler, Macrolane, penis enlargement

Accepted for publication September 14, 2012.



In recent years, men have begun to pay greater attention to their appearance.<sup>1</sup> The American Society for Aesthetic Plastic Surgery (ASAPS) statistics from 2010 show that cosmetic surgery among men has increased by more than 88% since 1997. In 2010, more than 750 000 cosmetic procedures were performed.<sup>1</sup> Penis enlargement is requested by men mainly because of shame and insecurity regarding their penis size in relation to other men. This is commonly referred to as *locker room syndrome*.<sup>2</sup>

Methods for penis enlargement can be classified into surgical, nonsurgical (filling), and mechanical. Each method has shown only relatively successful—and not always effective—results. In the past, the best results were obtained through the nonsurgical technique of lipofilling; however, the main drawback with this technique has been difficulty in obtaining a long-lasting result because fat tissue is subject to resorption at different rates.<sup>3</sup> Moreover, inoculated fat tends to yield cysts and microcalcifications, which are

particularly unpleasant in the penis, both aesthetically and tactically. No method is considered the gold standard.

Recently, an injectable, stabilized, hyaluronic acid (HA)–based gel of nonanimal origin (NASHA-based gel;

Drs Sito and Santorelli are plastic surgeons in private practice in Naples, Italy. Dr Marlino is a resident in the Department of Plastic Surgery, University Federico II, Naples, Italy.

## Corresponding Author:

Dr Sergio Marlino, Via Posillipo 239, 80123 Naples, Italy.  
E-mail: [sergiomarlino@msn.com](mailto:sergiomarlino@msn.com)



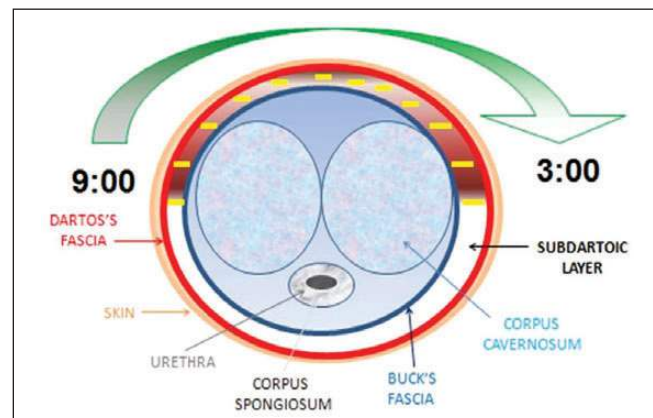
Scan this code with your smartphone to see the operative video. Need help? Visit [www.aestheticsurgeryjournal.com](http://www.aestheticsurgeryjournal.com).

Macrolane; Q-Med AB, Uppsala, Sweden) became available in 2 formulations—volume restoration factor (VRF) 20 and VRF 30—which are indicated for low volumetric increase and moderate volumetric increase, respectively. Macrolane is available in the United Kingdom and Europe but is not approved by the US Food and Drug Administration (FDA). The manufacturing process for NASHA-based gel involves cross-linking HA chains, resulting in a molecular network (HA gel) that remains biocompatible and that has a much longer half-life than endogenous HA.<sup>4</sup> Macrolane is slowly resorbed over 12 to 18 months.<sup>5</sup> The new formulations of this NASHA-based gel were developed for use in breast enhancement, volume restoration, and contouring of body surfaces.<sup>6</sup>

The penis consists of a fixed portion (the root of the penis) situated deep in the anterior perineum, a mobile portion (the body), and a swelled distal extremity (the glans). When the penis is flaccid, the glans is covered by a skin fold—the prepuce—that originates from the neck of the penis and is made up of an external layer that follows directly on the skin, covering the penis, folds onto itself, and then continues into the internal layer. The vascular supply of penile erectile tissues is provided by paired branches of the internal pudendal artery, by either the perineal artery (which supplies the corpus spongiosum) or the cavernosal artery (which supplies the corpora cavernosa). The dorsal artery of the penis (another terminal branch of the internal pudendal artery) supplies the skin, Buck's fascia, the tunica albuginea, and the corpus spongiosum and is located deep to Buck's fascia. The arteries give off circumflex branches to the corpus spongiosum and corpora cavernosa. The proximal perineal branch of the external pudendal artery supplies blood to the perineal skin and the scrotum.<sup>7</sup> The veins of the penis include a system of superficial veins that mostly flow into the superficial dorsal vein, along with the deep veins that originate from the corpora cavernosa and are tributaries to the deep dorsal vein, the deep veins, and the urethral veins.

The structure of the penis consists of particular erectile formations: the corpora cavernosa and the corpus spongiosum of the urethra. These formations are kept together and surrounded by a complex of “wrappers.” The corpora cavernosa are made up of a fibrous wrapper, the tunica albuginea, and cavernous (or erectile) tissue. On the free side of the penis, the corpora cavernosa wrappers are represented (from the outside to the inside) by skin, subcutis (dartos), and fascia of the penis (Buck's fascia). Both layers continue into the prepuce. The dartos layer represents the sliding surface of the skin and is made up of lax and fat-free connective tissue. The plane between the dartos fascia and Buck's fascia is a relatively avascular cleavage plane that is very easy to detach or undermine (Figure 1).<sup>8</sup>

In this study, we propose a technique for penis enlargement using Macrolane VRF 30 that is infiltrated in an emicircumferential way, clockwise on the dorsum of the penis from 9 o'clock to 3 o'clock, and we assess the safety and effectiveness of this procedure in a series of patients



**Figure 1.** Schematic cross-sectional diagram of the penis. The yellow lines show the space created above the Buck's fascia where the substance is released.

treated in the authors' private clinic. This technique is also compared with lipofilling.

## METHODS

We retrospectively examined the charts of 83 consecutive patients who presented for penis enlargement between December 2007 and July 2011. Patients were treated with either our Macrolane injection technique ( $n = 56$ ) or lipofilling ( $n = 27$ ). This study was not approved by any internal review board (IRB). Patients provided informed consent. Pretreatment penis circumference measurements ranged from 6.5 to 14 cm. In terms of length, 2 penises were considered micropenises (shorter than 7 cm), 33 were considered small (7–11 cm), and 48 were considered normal (11–14 cm).

All patients were evaluated with a semistructured interview that assessed family background as well as medical and surgical histories. Patient psychological suitability was assessed using the Stress, Target, Envision, Proactive (S.T.E.P.) approach suggested by Elsaie<sup>9</sup>: identify the patient *stressors* and specify their importance; let the patient *target* (specify) the area needed for correction (ensure the goals are realistic and attainable; otherwise, explain expected outcome); ask the patient to *envision* how his perceptions, emotions, and life would be different/better after the intervention; and if clear, attainable goals and realistic expectations are present, be *proactive* and devise a specific treatment plan for the patient. Questions regarding marital status, work type, and job satisfaction provided further vital information when assessing patient overall psychological suitability. Psychologically, the ideal study candidate had no obvious psychopathology, clearly defined areas of dissatisfaction, realistic expectations, and self-motivation.

All patients in this study were psychologically suitable and sought penis augmentation primarily for aesthetic reasons; none reported erectile dysfunction, only locker room syndrome. Patients were advised that treatment was mainly for circumferential enlargement: the effect on

flaccid penis length would be secondary, and there would be no effect on the length of the penis during erection. All patients voluntarily participated in evaluation and treatment.

Flaccid penile length was measured in a warm, quiet room. Penile length was defined as the distance from the pubopenile skin junction at the dorsum to the tip of the glans. Stretched flaccid length was measured under maximal extension of the phallus, according to the description by Wessells et al.<sup>10</sup> A rigid ruler was used, except when measuring penile circumference, to avoid measurement error as a result of penile curvature. Penis circumference was measured with a tape at the mid-shaft level, with the penis at normal rest.<sup>11</sup>

The lipofilling technique used in our study involved the injection of 250 mL saline fluid, 0.2% lidocaine with 1:250 000 epinephrine of saline, into the donor site; the suprapubic area was the common harvest site used to enhance penis length. Fat was harvested through gentle aspiration with a 60-mL syringe and a 3-mm cannula using 20 mL of negative pressure, as measured by the scale imprinted on the side of the syringe. The harvested fat was then processed by decantation and infiltrated using a 20-mL syringe.

Our HA enlargement technique consisted of injection of Macrolane into the dorsum of the penis. The injection method for Macrolane is the same as the one used for lipofilling. The treatment was performed under local anesthesia through the injection of 2.5 mL lidocaine into the dorsal nerve at the base of the penis.<sup>12</sup> A 12-gauge cannula was introduced through a median stab incision created by a No. 11 blade at the base of the dorsal surface of the penis. With this cannula, the dartoic layer was first detached to recreate a space within the subcutaneous layer above Buck's fascia. This detachment was performed clockwise on the dorsum of the penis from 9 o'clock to 3 o'clock (Figure 1). Once the detachment was made, approximately 30 to 40 mL of filler was injected into the space. The substance was released uniformly by retrograde administration, avoiding infiltration in the corpora cavernosa. A video of this procedure is available at [www.aestheticsurgeryjournal.com](http://www.aestheticsurgeryjournal.com). You may also use any smartphone to scan the code on the first page of this article to be taken directly to the video on [www.youtube.com](http://www.youtube.com).

Once the operation was completed, the access point of the cannula was sutured with 4-0 nylon. Patients were then advised to place the penis vertically into their underwear (briefs) to facilitate venous return. Two days post-treatment, the patients could begin to massage the penis to smooth possible irregularities. Macrolane is malleable and easily able to adapt to manipulation, even a few days after injection. During the postoperative period, patients were advised to abstain from sexual intercourse for 15 days if Macrolane was used and for 30 days if lipofilling was performed. Follow-up was carried out at 7 days post-treatment (the day of stitch removal) and 15 days, 1 month, 6 months, 1 year, and 2 years after the procedure. At 1-year follow-up, measurements were taken and patient

satisfaction was assessed using a standardized patient satisfaction questionnaire examining patients' feelings about the facility and their treatment.

## RESULTS

Patient ages ranged from 26 to 42 years (average, 32.98 years). Mean operating time was 18 minutes for Macrolane and 48 minutes for lipofilling. Average duration of follow-up was 24 months. Seventy-two patients reported that they were "very satisfied" with the result (86.7%), 7 patients were "satisfied" (8.4%), and 4 patients were "unsatisfied" (4.8%). Of the unsatisfied group, 2 patients were treated with Macrolane (3.5% of the HA-treated group) and 2 with lipofilling (7.4% of lipofilling group).

Circumferential enlargement ranged from 3.2 to 4.5 cm, with a decrement reported by patients during erection. In all patients, the increase in the stretched penis length ranged from 1.8 to 3.6 cm (Figures 2 and 3). Measurements were not taken by the physician with the penis in an erect state. At follow-up, 3 patients with a history of premature ejaculation reported longer duration of sexual intercourse.<sup>13,14</sup>

No complications were observed in patients treated with Macrolane, but a granuloma formed in 8 patients treated with lipofilling. The symptoms of 5 of these patients resolved spontaneously within 6 months with the help of massage; 2 patients reported no relief of symptoms from massage, and fat necrosis with progressive skin loss occurred in 1 patient after 20 days. That patient's wounds were treated conservatively with weekly dressing, and secondary healing occurred after 3 months (Figure 4).

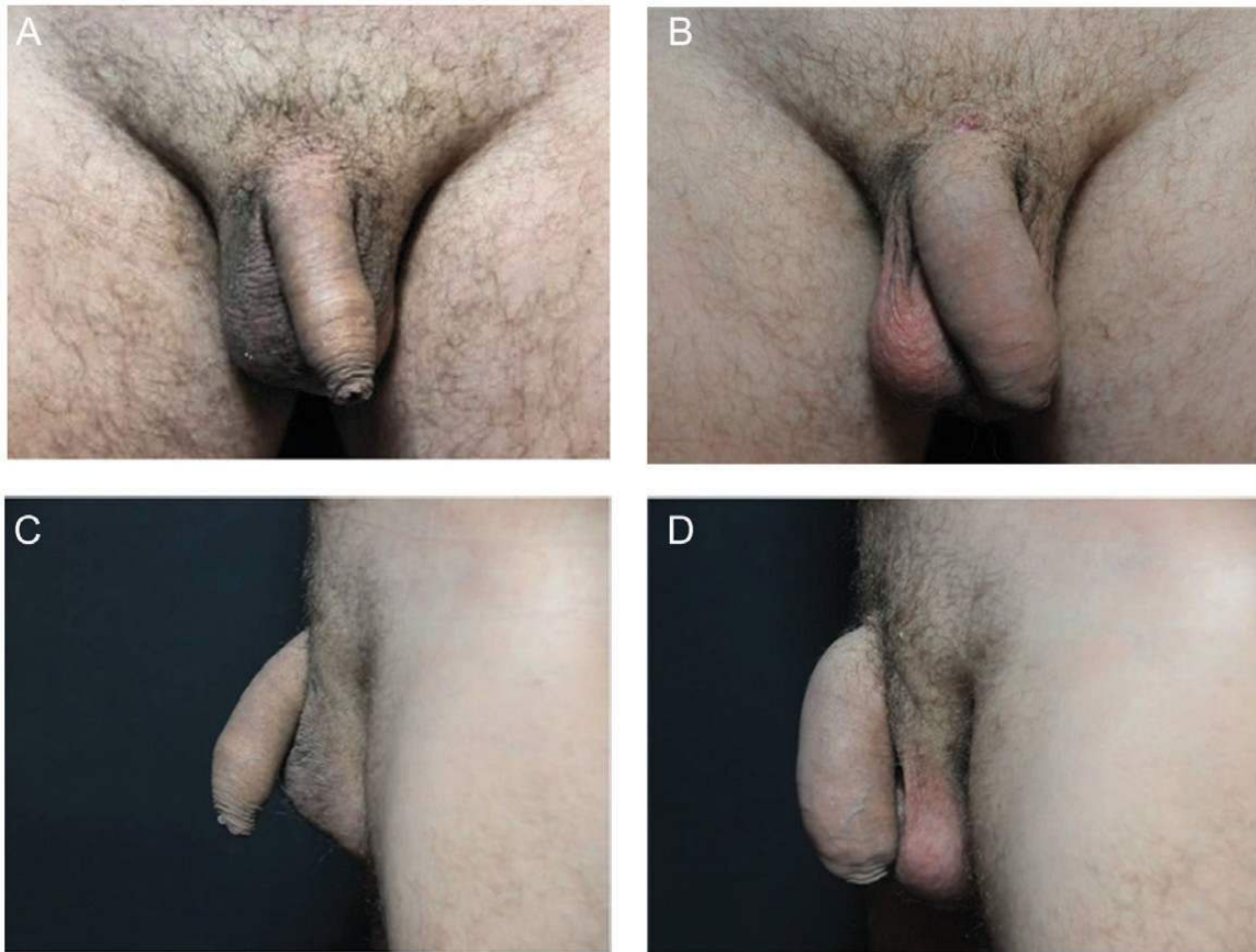
The percentage of HA resorption and durability was not variable, as it is with lipofilling. In fact, 50% of patients treated with Macrolane maintained penis dimension at 12 months' follow-up, whereas patients treated with lipofilling had a variable percentage of fat resorption and durability (Table 1).

## DISCUSSION

Many publications have reported on the size of penises in the Western world. These investigations have indicated that the average length of a nonerect penis is between 8.21 and 9.22 cm, between 10.88 and 12.50 cm for a stretched penis, and between 12.90 and 14.48 cm for an erect penis.<sup>15-17</sup> The average circumference of a nonerect penis is between 9.71 and 10.00 cm, but according to the only available study conducted in the West, the average circumference of an erect penis is 12.30 cm.<sup>10</sup>

The scientific community has always been interested in a technique to represent the gold standard in increasing penis size. The ideal technique would be nonsurgical, with a satisfactory and predictable result, a low rate of complications, and longevity of the results. In recent years, lipofilling has been one of the most useful procedures.<sup>18</sup> This technique





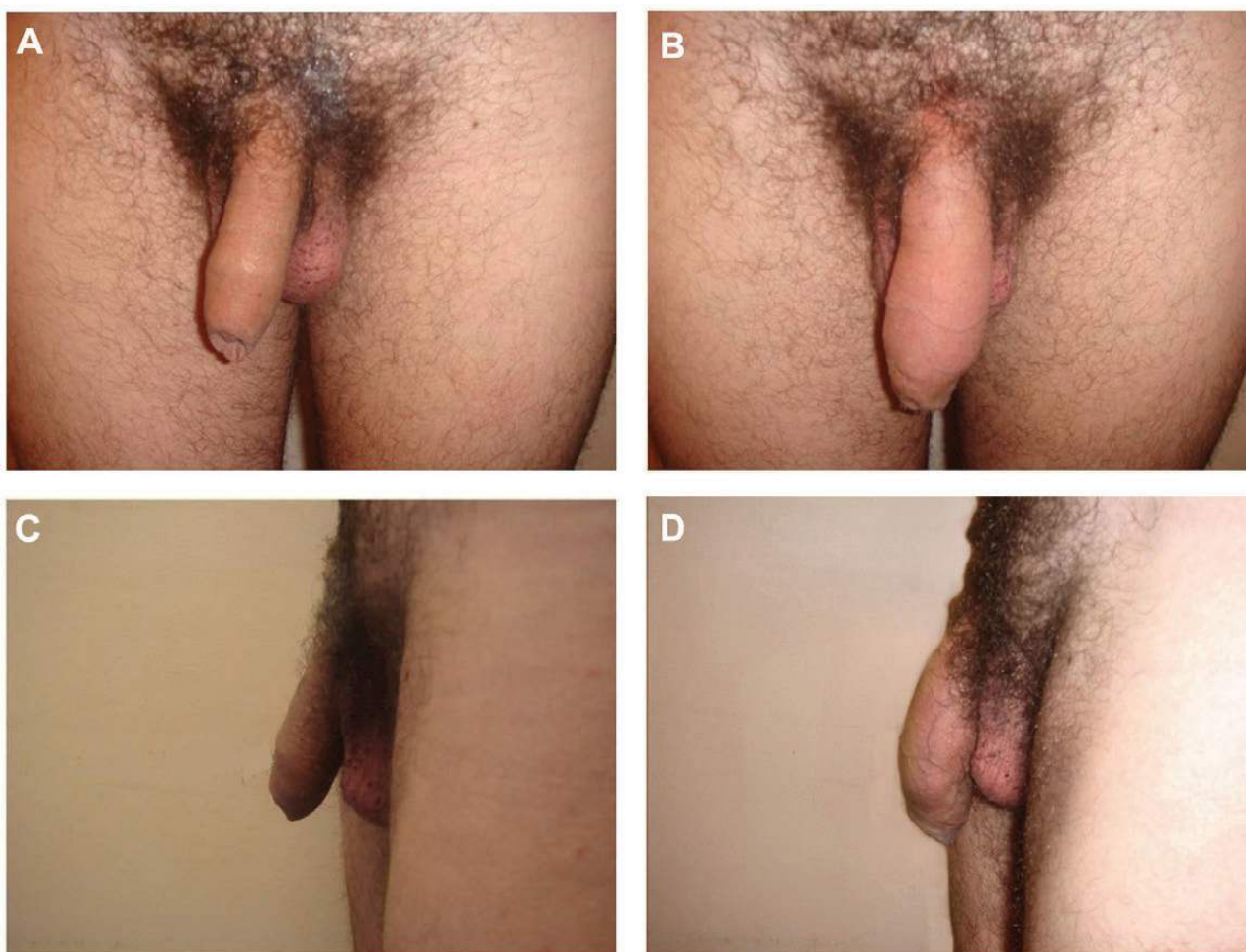
**Figure 2.** (A, C) This 34-year-old man presented with “locker room syndrome”; he was concerned about the size of his penis in comparison to other men. (B, D) Twelve months after injection of 30 mL Macrolane.

consists of 3 steps: (1) harvesting the patient’s own fat with a specific liposuction cannula and special devices from a particular site, referred to as a “donor site”; (2) processing the fat using centrifugation or simple decantation to obtain concentrated fat; and (3) injecting the fat in another area called the “recipient site.” However, the results with lipofilling are not predictable, and the fat graft has a tendency to produce a granuloma, as was seen in 8 cases in the current study. There is also the need for a donor site. Macrolane, derived from hyaluronic acid, is well tolerated by the body, and its resorption only occurs after 12 to 18 months.<sup>5</sup> As Macrolane leaves the body, neither scars nor fibrosis are seen, and the procedure to inject Macrolane can be repeated several times because it does not require extensive manipulation of fat and allows for remarkably short operation times (18 minutes for Macrolane vs 48 minutes for lipofilling).

Our study showed a high level of patient satisfaction with both procedures, but a higher rate of complications in the group treated with lipofilling (3.5% for Macrolane vs 7.4%

for lipofilling). Furthermore, results with Macrolane were more predictable, and the method we have described proved easy to use, widely repeatable, and complication free.

Many doctors are reluctant to recommend Macrolane, or any other injectable substance, for penile injection without animal studies to confirm its safety. The manufacturer, Q-Med, recently distributed a letter drawing attention to a recent update to the Macrolane Instructions for Use (IFU). The 2 main changes are further clarification regarding radiologic examination and treatment in the penis. A warning was added against use of Macrolane for the penis because the benefit-to-risk ratio has not been adequately investigated in prospective clinical studies. Specifically, in the latest update to the Macrolane IFU, the indication will be changed to read that it “should not be used for the hands and the penis because the benefit/risk has not been adequately investigated in prospective clinical studies.” Information regarding rare cases of erectile difficulty after treatment in the penis has been reported



**Figure 3.** (A, C) This 36-year-old man presented with “locker room syndrome”; he was concerned about the size of his penis in comparison to other men. (B, D) Twelve months after lipofilling with 34 mL of fat.

and included in the IFU.<sup>19</sup> These cases are under review by a group of experts in plastic surgery and urology. A number of investigations have been undertaken, and a clear understanding of the mechanism for this complication has not yet been published. One hypothesis is that HA has entered into the corpora cavernosa and blocked the venous sphincters. It is also possible that Macrolane may have penetrated into an emissary or deeper dorsal vein. For this reason, we use a blunt cannula instead of a needle to avoid intravascular injection.

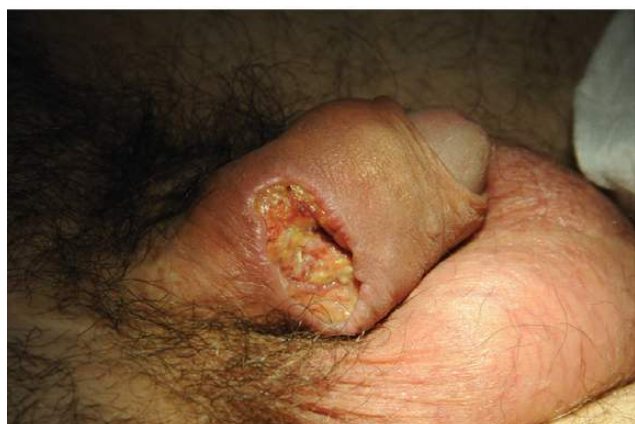We are convinced that Macrolane infiltration in the right plane is the key to avoiding erectile complications. The product should be placed in the space between the dartos layer and Buck’s fascia, which is very easy to detach before injection. Infiltration into the corpora cavernosa, at least in the authors’ opinion, could be a cause of complications and should be avoided.

The limitations of the current study include the absence of imaging studies (ultrasound and magnetic resonance imaging) to evaluate the area to be enhanced

before treatment. Additional studies are needed to assess the safety and effectiveness of treatment with Macrolane in a larger cohort of patients with longer follow-up times.

## CONCLUSIONS

Emicircumferential enlargement with use of Macrolane has predictable results and a low rate of complications, offers durability, and is a rapid procedure; however, the results are not definitive. The Macrolane safety profile and duration reported herein are compatible with previous clinical experience with Macrolane for breast enhancement and body sculpture. No previously published articles have discussed the use of Macrolane in penis enlargement. The results of our study showed that emicircumferential penis enlargement with Macrolane could be effective, safe, and reproducible; however, frequent repeat treatment is necessary. This need to repeat the procedure is less than



**Figure 4.** This 40-year-old man presented with “locker room syndrome”; he was concerned about the size of his penis in comparison to other men. Twenty days after lipofilling with 32 ml of fat, fat necrosis with progressive skin loss occurred. The patient’s wounds were treated conservatively and healing was complete by secondary intention after 3 months.

**Table 1.** Results of Macrolane Treatment vs Lipofilling

	Macrolane	Lipofilling
Patients	56	27
Mean operating time, min	18	48
Satisfaction ratings, No.		
Very satisfied	50	22
Satisfied	4	3
Unsatisfied	2	2
Complication rates, No.		
Hematoma	0	2
Seroma	0	1
Infection	0	0
Calcification	0	7 (5 spontaneously resolved)
Other problems	0	1 fat necrosis with skin loss
Duration of effect at 12 months	50% at 12 mo	Unpredictable
Required sexual abstinence	14 days	21 days

desirable; however, in the authors’ opinion, the ease of the procedure makes this necessity more acceptable.

## Disclosures

Giuseppe Sito, MD, is a consultant for Q-Med (the manufacturer of the product discussed in this article) and receives

payment for lectures and travel on behalf of the company. Neither Sergio Marlino, MD, nor Adriano Santorelli, MD, has a financial interest in the company or its products, or relationships, stock holdings, or consultant positions with any other industry companies.

## Funding

No funding was provided for the writing of the manuscript. This manuscript discusses off-label use of a hyaluronic acid product (Macrolane; Q-Med AB, Uppsala, Sweden). This application of Macrolane is not FDA-approved and not recommended for use in the penis.

## REFERENCES

1. American Society for Aesthetic Plastic Surgery. Cosmetic Surgery National Data Bank 2010 statistics. <http://www.surgery.org/media/statistics>.
2. Vardi Y, Lowenstein L. Penile enlargement surgery—fact or illusion? *Nature Clin Prac Urol*. 2005;2:114-115.
3. Panfilov DE. Augmentative phalloplasty. *Aesthetic Plast Surg*. 2006;30:183-197.
4. Hedén P. The promising future of hyaluronic acid for body contouring. Presented at: Anti-Aging Medicine World Congress 2007; March 22-24, 2007; Monaco.
5. Bhat W, Akhtar S, Akali A. Breast augmentation with implants following previous enhancement with Macrolane™ filler injections. *Aesthetic Plast Surg*. 2011;35:670-671.
6. Hedén P, Olenius M, Tengvar M. Macrolane for breast enhancement: 12-month follow-up *Plast Reconstr Surg*. 2011;127:850-860.
7. Chaux A, Cubilla AL. Diagnosis and pathology of penile cancer. In: Muneer A, Arya M, Horenblas S, eds. *Textbook of Penile Cancer*. London: Springer-Verlag; 2011:27-68.
8. Brandes SB. Vascular anatomy of genital skin and the urethra: implications for urethral reconstruction. In: Brandes SB, ed. *Urethral Reconstructive Surgery*. Totowa, NJ: Humana; 2010:9-18.
9. Elsaie M. Psychological approach in cosmetic dermatology for optimum patient satisfaction *Indian J Dermatol*. 2010;55:127-129.
10. Wessells H, Lue TF, McAninch JW. Penile length in flaccid and erect states: guidelines for penile augmentation. *J Urol*. 1996;156:995-997.
11. Son H, Lee H, Huh JS, et al. Studies on self-esteem of penile size in young Korean military men. *Asian J Androl*. 2003;5:185-189.
12. Giorgio I, Mossetti V. General considerations for pediatric peripheral blocks. In: Chelly JD, ed. *Peripheral Nerve Blocks: A Color Atlas*. Philadelphia, PA: Lippincott Williams & Wilkins; 2008:357-358.
13. Moon DG, Kwak TI, Cho HY, et al. Augmentation of glans penis using injectable hyaluronic acid gel. *Int J Impot Res*. 2003;15:456-460.
14. Kim JJ, Kwak TI, Jeon BG, et al. Effects of glans penis augmentation using hyaluronic acid gel for premature ejaculation. *Int J Impot Res*. 2004;16:547-551.
15. Ponchietti R, Mondaini N, Bonafè M, et al. Penile length and circumference: a study on 3,300 young Italian males. *Eur Urol*. 2001;39:183-186.

16. Spyropoulos E, Borousas D, Mavrikos S, et al. Size of external genital organs and somatometric parameters among physically normal men younger than 40 years old. *Urology*. 2002;60:485-489.
17. Promodu K, Shanmughadas KV, Bhat S, et al. Penile length and circumference: an Indian study. *Int J Impot Res*. 2007;19:558-563.
18. Coleman SR. Structural fat grafts: the ideal filler? *Clin Plast Surg*. 2001;28:111-119.
19. Macrolane [instructions for use], VRF20 and VRF 30. Uppsala, Sweden: Q-Med AB; November 2011.