

Nonsurgical Methods for Penile Augmentation: A Systematic Review

Antoine Salloum, MD,*† Nagham Bazzi, MD,‡ and Roger Haber, MD*§

BACKGROUND There is no standardized approach for nonsurgical techniques for penile augmentation despite the increase of demand for this intervention.

OBJECTIVE To compare the efficacy and safety between different injection techniques.

MATERIALS AND METHODS On October 8, 2019, a literature search was performed on PubMed, Embase, Ovid, and Cochrane database. All articles describing penile augmentation were included.

RESULTS Thirteen studies were included in this article with a total of 1,311 patients. Five studies were prospective cohort. The most commonly described technique was hyaluronic acid fillers with a total of 4 articles and 205 patients. The mean injected volume ranged from 20 to 40 mL. In all included studies, a minority of patients had side effects, but some had disabling complications.

CONCLUSION There are no defined clinical guidelines for penile augmentation techniques implemented yet. Hyaluronic acid seems to be safe, efficient, and with a high satisfaction score. Further randomized control trials are warranted.

EBM (LEVEL OF EVIDENCE-BASED MEDICINE) 2a.

Throughout history, since the time of the prehistoric cave dwellers and the Kama Sutra, penile size was regarded as a symbol of power and strength for men and had a significant effect on their self-esteem.¹ It is no surprise that even today penile size is of great importance.

Procedures enhancing penile size can be classified into surgical, nonsurgical, and mechanical procedures. Nowadays, nonsurgical procedures are increasing because of their decreased risk compared with the surgical procedures.² A recent study showed that among men who suffer from small penis, only 3.6% (9/250) chose to seek surgical intervention.³

There is no standardized procedure for penile augmentation, but there is a great variety of procedures with little scientific evidence.⁴ This systematic review aims to identify the safety and effectiveness of various nonsurgical procedures and provide a current guide for practice based on the best available evidence of fillers for penile enlargement.

Methods

A priori protocol was approved by all authors. On October 8, 2019, a literature search was conducted and focused on nonsurgical methods of penile augmentation for aesthetic

purposes. The PubMed, Embase, Cochrane, and Ovid databases were searched, using various combination of the following free text: “penile augmentation,” “penile lengthening,” “penis enlargement,” “fillers complications,” “penis size,” “penis injections,” and “small penis.” Articles were evaluated by the authors (A.S. and N.B.), and the most relevant articles were selected according to their titles and abstracts.

Results

Among the 294 articles matching our search terms, 14 articles were included. The stepwise approach for article selection is illustrated in **Supplemental Digital Content 1**, Figure S1, <http://links.lww.com/DSS/A631>.

Included articles were published between 2007 and 2019, with a total of 1,331 patients.

The mean age of patients was 42.6 (range between 20 and 72) years. None of these studies had a control group (See **Supplemental Digital Content 2**, Table S1, <http://links.lww.com/DSS/A632>).

The main indication for penile augmentation was aesthetic purposes, dissatisfaction with penis size, and the desire to have a bigger one.

The most commonly used penile augmentation technique is hyaluronic acid (HA) fillers using a fanning technique (Back and Forth) with a total of 4 articles and 205 patients.^{5–8} The mean volume was 20 mL and 30 to 40 mL for penile augmentation and 2 mL for glans penis augmentation. Gel was injected between dartos fascia and Buck’s fascia (Figures 1 and 2). Injections were performed in the posterior and lateral side to avoid urethral injury. After the injection, the penis was massaged for even distribution. Oral antibiotics were indicated for 3 days or 1

From the *Department of Dermatology, Saint George Hospital University Medical Center, Beirut, Lebanon; †Dermatologic Surgicenter, Philadelphia, Pennsylvania; ‡Faculty of Medicine, Lebanese University, Beirut, Lebanon; §Department of Dermatology, Balamand University, El-Koura, Lebanon

The authors have indicated no significant interest with commercial supporters. Address correspondence and reprint requests to: Roger Haber, MD, Faculty of Medicine, Balamand University, El-Koura, Lebanon 00000, or e-mail: rnhaber@stgeorgehospital.org

Supplemental digital content is available for this article. Direct URL citations appear in the printed text and are provided in the HTML and PDF versions of this article on the journal’s Web site (www.dermatologicsurgery.org).

<http://dx.doi.org/10.1097/DSS.0000000000002816>

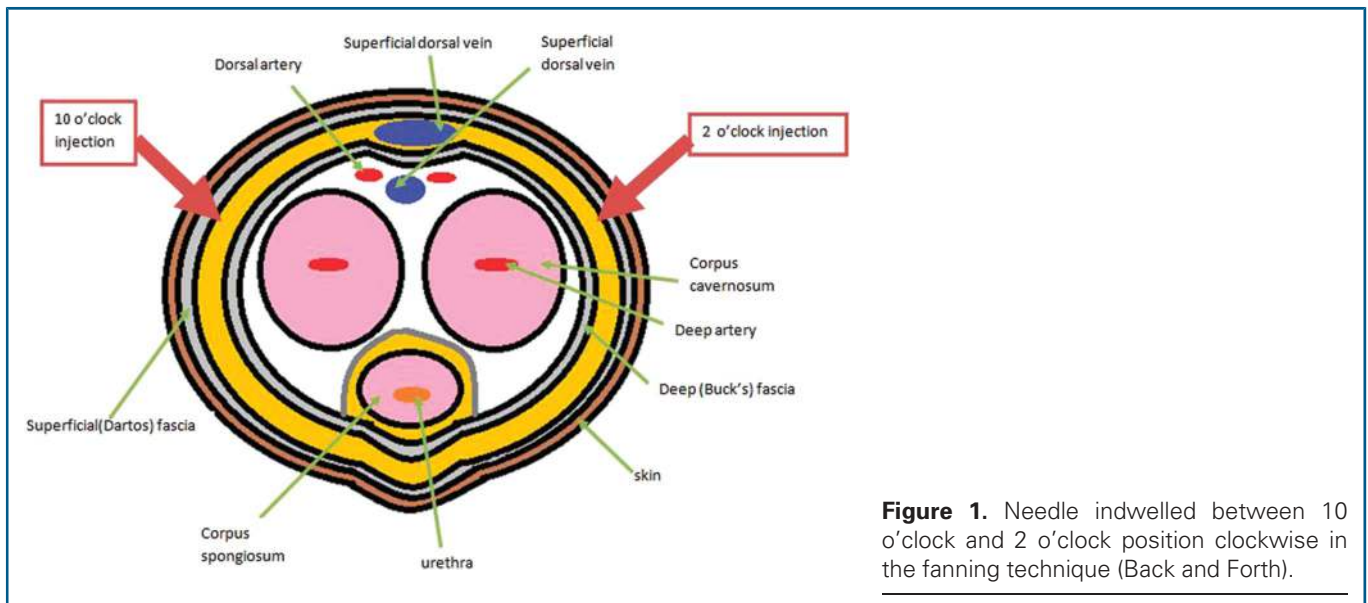


Figure 1. Needle indwelled between 10 o'clock and 2 o'clock position clockwise in the fanning technique (Back and Forth).

week with acetaminophen.^{5,6} After injection, an elastic support bandage was applied. For glans penis augmentation, Moon and colleagues described 2 techniques: the fanning technique and the linear threading technique that requires more punctures and cause mucosal tearing and other complications.⁷

No serious events were found in HA techniques.⁵⁻⁸ Supplemental Digital Content 3, Table S2, <http://links.lww.com/DSS/A633>.

The method used for lipofilling injection is same as the one used for HA injection.⁸ Fat was harvested from the suprapubic area and then processed by decantation and infiltrated using a 20 mL syringe.

Two articles described an injectable silicone technique for penile augmentation.^{9,10} In the case report, the injected volume was 50 mL in the blunt tip.⁹

On the other hand, 5 mL was injected in every session in the cohort study published by Yacobi and colleagues. The silicone oil was injected into the areolar tissue between the tented penile skin and Buck's fascia on the dorsal and lateral side of the penis. A patient needed 4 to 6 sessions with 30 days interval between each session. After each session, the penis was massaged, and a support bandage was applied for 2 weeks.¹⁰

Silicone injection adverse events were mild bruising and a complete necrosis of dorsal part of penile skin and soft tissue.^{9,10}

A polylactic acid (PLA) filler was used in 2 articles^{5,11} for penile augmentation. The same technique described above for HA injection was used for the PLA technique. The mean volume injected was 20 mL. An elastic support bandage was applied, and oral antibiotics with nonsteroidal anti-

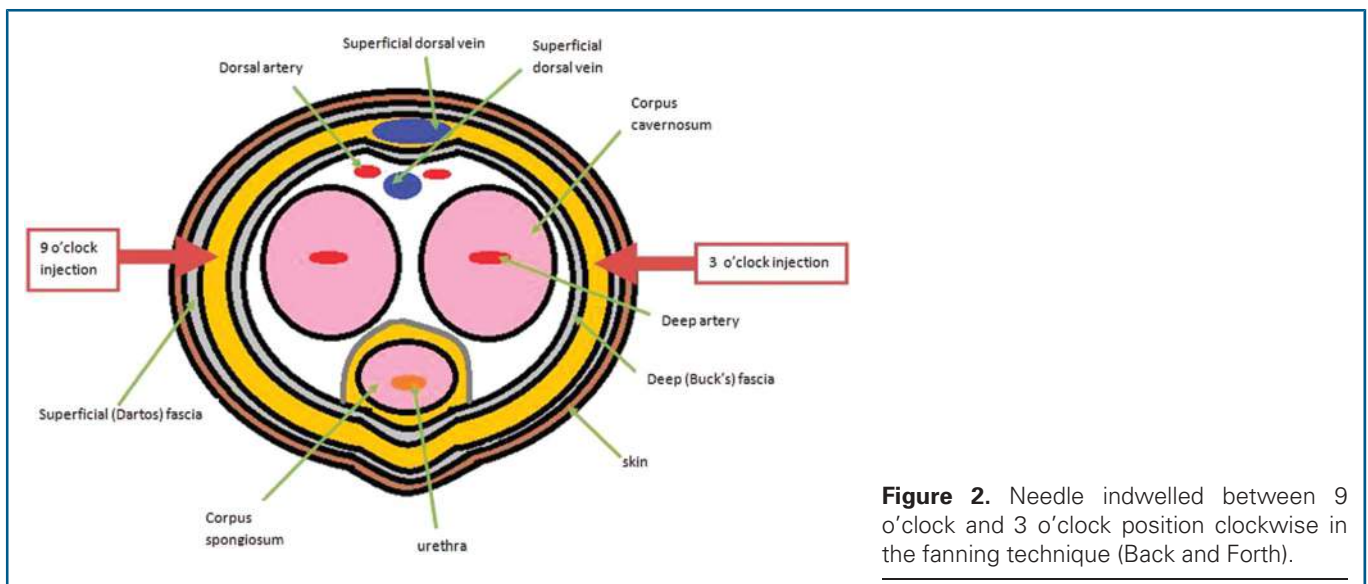


Figure 2. Needle indwelled between 9 o'clock and 3 o'clock position clockwise in the fanning technique (Back and Forth).

inflammatory drugs were prescribed for 3 days. Serious adverse events were not reported.¹¹ The satisfaction level increased by more than 50% after 6 months¹¹

Polymethylmethacrylate was described in Casavantes and colleagues¹² and Kim and colleagues¹³ articles. Uncircumcised patients were premedicated with lorazepam 1 mg sublingually and selected circumcised patients received betamethasone 1 mL intramuscular injection.¹² Kim and colleagues¹³ used the fanning technique to inject 23.7 mL between dartos fascia and Buck's fascia.

Casavantes and colleagues' technique was described in Figures 3 and 4. In a healthy patient, the mean injected volume in each session was 20 mL, and every patient needed 2 sessions minimum to 3 maximum with 6 weeks interval.

Half (52%) of the patients had irregularities in the penis skin after the injection; 3 patients (0.4%) had one polymethylmethacrylate nodule removed surgically, and 2 patients had exudates for longer than 72 hours.¹²

The overall satisfaction rate was high (8.7/10), and only 5% were dissatisfied.

Yang and colleagues¹⁴ described the technique of cross-linked dextran gels for glans penis augmentation. The gel was injected in the lamina propria of the glans penis posteriorly and laterally with an indwelled needle at the 1 o'clock and 11 o'clock position (Figure 5). The mean injected volume was 6.6 mL ± 0.9 mL. All patients who used dextran gels had mild glandular pain and edema,¹⁴ and most patients were satisfied with the results.

Al-Ansari and colleagues¹⁵ reported 8 case reports of subcutaneous cod oil liver injection for penile augmentation. Complications ranged from paraphimosis to abscess formation and necrosis of penile skin. Most patients underwent 2 major treatment, 1 emergent initial surgical treatment to drain the abscess, and second definitive treatment using a local penile flap (5 patients) and V-Y plasty (2 patients). One patient alone needed circumcision.

Two articles^{16,17} described 2 case reports of paraffinoma. The patient presented with penile pain,^{16,17} acute urinary retention,¹⁶ and phimotic foreskin with ulceration all over the penile skin.^{16,17} Injections were performed by a nonmedical person.^{16,17}

Penile surgery was immediately performed to remove the scared tissue. The postoperative course was uneventful.^{16,17}

Subcutaneous metallic mercury injection for penile augmentation was presented in Oh and colleagues'¹⁸ study. Patient's serum mercury level was 42 g/dL, and his urinary mercury excretion was 875 g/dL/d.¹⁸ His penis was swollen with an ulcerative lesion on the dorsal surface, with a pus-like discharge of silver-colored metallic material. Patient underwent total phallectomy and perineal urethrostomy, followed by chelation therapy.

Articles that measured circumference size or glans penis area were grouped in **Supplemental Digital Content 4**, Table S3, <http://links.lww.com/DSS/A634>.

The mean penile preinjection circumference (mid-shaft) was 7.9 cm. In an HA filler, the mean penile postinjection circumference was 10.88 cm^{5,6} in ≤18 months and

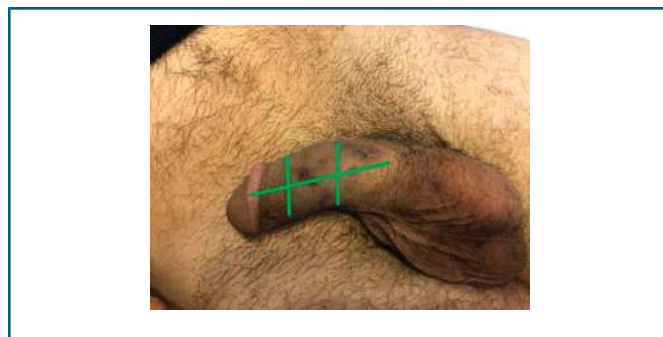

Figure 3. Casavantes and colleagues' technique: corpus spongiosum is marked with 2 longitudinal and 2 to 3 transversal lines.

increased from baseline by 3.2 to 4.5 cm in 24 months.⁸ In the PLA technique, the mean circumference size post-injection was 10.1 cm.^{5,11}

Various satisfaction scales were used; the most common is the grading scale from 0 to 4 in the order of increasing satisfaction.^{6,14} Overall, most patients were satisfied, and only 4.8% of patients were unsatisfied with the penis size using an HA filler.⁸ A significant difference ($p < .05$) was noted in the satisfaction rate between the HA group (3.88) and PLA group (3.41) at 48 weeks.⁵

Discussion

“Lunch time procedures” refer to the minimal invasive cosmetological procedures that are now more demanded for penile augmentation because of their minimal side effects.¹⁹ To the best of our knowledge, this is the first systematic review to assess only nonsurgical techniques for penile augmentation for aesthetics purposes.

We found that the mean age of patients was 42.5 years. This can be explained by the fact that penile erectile dysfunction due to penis aging is more prevalent between ages 40 and 70²⁰ years, and its prevalence is 50% at the fifth decade.²¹ However, penile augmentation is not recommended just as an antiaging treatment because in our article patients in their second decade performed this procedure for beautification purposes.

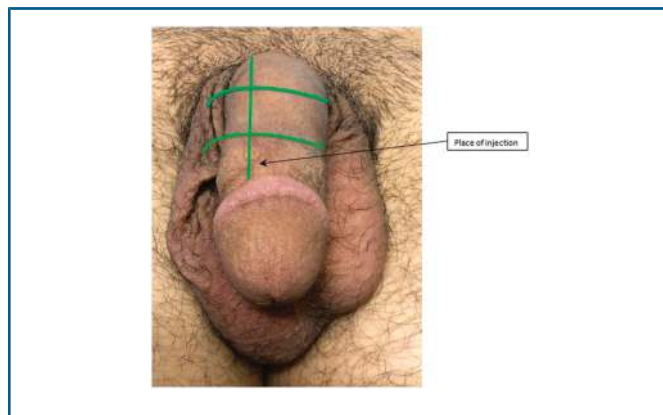


Figure 4. Nine sections and 6 entry points were used for a full treatment in healthy patients.

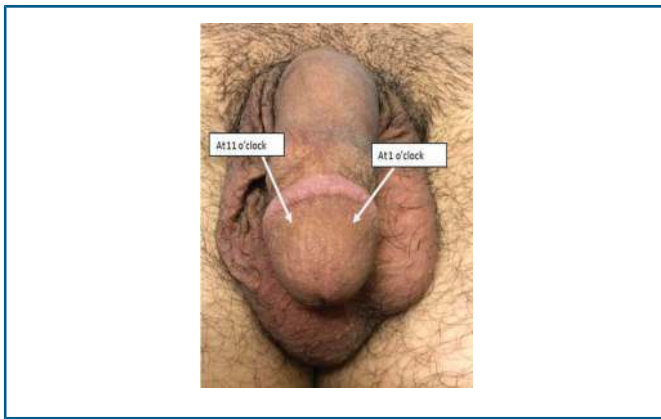


Figure 5. The gel was injected in the lamina propria of the glans penis posteriorly and laterally with an indwelled needle at the 1 o'clock and 11 o'clock position.

The most commonly used substance was an HA filler, and the most commonly used technique was Back and Forth (the fanning technique). Injected volumes varied between 20 mL and 40 mL for penile augmentation and 2 mL for glans penis augmentation. The volumes were injected only on the lateral and posterior side of the penis to avoid urethral injury, and the needle was indwelled at different angles to avoid vessel injuries. Injections were performed between dartos fascia and Buck's fascia (Figures 1 and 2).

An HA filler is also used for penile pathological diseases, is effective for premature ejaculation,²² and is a promising treatment for Peyronie disease, a localized fibrotic disorder.²³

Hyaluronic acid has a durability of 12 to 18 months²⁴ and can be reversed with hyaluronidase.²⁵

Poly-L-lactic acid (PLLA) works by stimulating an immune response and fibroblast proliferation forming new connective tissue with collagen deposits.²⁶ This is why a PLLA effect last even after the resorption of the filler,^{27,28} which is opposite to the temporary effect of HA.²⁹

Liquid silicone can be used for soft-tissue augmentation³⁰ and was used to correct the penis retracted skin.³¹ Silicone induces a delayed immune reaction that progress to a fibrotic reaction, and granulomas can be formed.³²⁻³⁴ Many adverse reactions were reported,³⁵⁻⁴² such as a severe alveolar hemorrhage,³⁶ lethal silicone embolization syndrome,⁴⁰ penile granuloma,^{39,41,42} and penis skin necrosis.³⁷

Limitations

There are many limitations in this study. None of the articles included had a group control, thus we could not do a meta-analysis, and our study was limited to a form of pooled data. The variability between scales used to measure satisfaction, the different date of follow-up, and other measurements restricted our interstudy comparison. Only the published data on the database mentioned above were included, which is also another limitation. Another bias was the location of included articles; more than half of them were in Korea, although we tried to make it multicenter as possible.

Conclusion

Penile augmentation seems to be a safe and well-tolerated procedure. It has many indications and is not limited to aesthetic purposes. Every technique had a side effect, but the safer technique was HA, and it had the higher satisfaction score. Further randomized control studies assessing HA fillers and other fillers are now warranted.

References

1. Veale D, Miles S, Read J, Troglia A, et al. Sexual functioning and behavior of men with body dysmorphic disorder concerning penis size compared with men anxious about penis size and with controls: a cohort study. *Sex Med* 2015;3:147-55.
2. Yang DY, Lee WK, Kim SC. Tolerability and efficacy of newly developed penile injection of cross-linked dextran and polymethylmethacrylate mixture on penile enhancement: 6 months follow-up. *Int J Impot Res* 2013;25:99-103.
3. Ghanem H, Shamloul R, Khodeir F, ElShafie H, et al. Structured management and counseling for patients with a complaint of a small penis. *J Sex Med* 2007;4:1322-7.
4. Vardi Y. Is penile enlargement an ethical procedure for patients with a normal-sized penis?. *Eur Urol* 2006;49:609-11.
5. Yang DY, Ko K, Lee SH, Lee WK. A comparison of the efficacy and safety between hyaluronic acid and poly(lactic acid) filler injection in penile augmentation: a multicenter, patient/evaluator-blinded, randomized trial. *J Sex Med* 2019;16:577-85.
6. Kwak TI, Oh M, Kim JJ, Moon DG. The effects of penile girth enhancement using injectable hyaluronic acid gel, a filler. *J Sex Med* 2011;8:3407-13.
7. Moon du G, Kwak TI, Kim JJ. Glans penis augmentation using hyaluronic acid gel as an injectable filler. *World J Mens Health* 2015;33:50-61.
8. Sito G, Marlino S, Santorelli A. Use of Macrolane VRF 30 in circumferential penis enlargement. *Aesthet Surg J* 2013;33:258-64.
9. Shin YS, You JH, Choi H, Zhang LT, et al. An unusual course after injection of industrial silicone for penile augmentation. *Can Urol Assoc J* 2015;9:E145-7.
10. Yacobi Y, Tsivian A, Grinberg R, Kessler O. Short-term results of incremental penile girth enhancement using liquid injectable silicone: words of praise for a change. *Asian J Androl* 2007;9:408-13.
11. Yang DY, Ko K, Lee SH, Moon DG, et al. Efficacy and safety of a newly developed polylactic acid microsphere as an injectable bulking agent for penile augmentation: 18-months follow-up. *Int J Impot Res* 2017;29:136-41.
12. Casavantes L, Lemperle G, Morales P. Penile girth enhancement with polymethylmethacrylate-based soft tissue fillers. *J Sex Med* 2016;13:1414-22.
13. Kim MT, Ko K, Lee WK, Kim SC, et al. Long-Term safety and longevity of a mixture of polymethyl methacrylate and cross-linked dextran (Lipen-10) after penile augmentation: extension study from six to 18 Months of follow-up. *World J Mens Health* 2015;33:202-8.
14. Yang DY, Ko K, Lee SH, Moon DG, et al. Efficacy and safety of newly developed cross-linked dextran gel injection for glans penis augmentation with a novel technique. *Asian J Androl* 2018;20:80-4.
15. Al-Ansari AA, Shamsodini A, Talib RA, Gul T, et al. Subcutaneous cod liver oil injection for penile augmentation: review of literature and report of eight cases. *Urology* 2010;75:1181-4.
16. De Siami M, Selvaggio O, Di Fino G, Liuzzi G, et al. An unusual delayed complication of paraffin self-injection for penile girth augmentation. *BMC Urol* 2013;13:66.
17. Singh M, Singh V, Moh CLC. Penile paraffinoma. *Med J Malaysia* 2015;70:361-2.
18. Oh KJ, Park K, Kang TW, Kwon DD, et al. Subcutaneous metallic mercury injection for penile augmentation. *Urology* 2007;69:185.e3-4.

19. Coskuner ER, Canter HI. Desire for penile girth enhancement and the effects of the self-injection of hyaluronic acid gel. *J Cutan Aesthet Surg* 2012;5:198–200.
20. Feldman HA, Goldstein I, Hatzichristou DG, Krane RJ, et al. Impotence and its medical and psychosocial correlates: results of the Massachusetts Male Aging Study. *J Urol* 1994;151:54–61.
21. Rajfer J. The aging penis: what is it trying to tell us? *Transl Androl Urol* 2012;1:58–60.
22. Littara A, Palmieri B, Rottigni V, Iannitti T. A clinical study to assess the effectiveness of a hyaluronic acid-based procedure for treatment of premature ejaculation. *Int J Impot Res* 2013;25:117–20.
23. Zucchi A, Costantini E, Cai T, Cavallini G, et al. Intralesional injection of hyaluronic acid in patients affected with Peyronie's disease: preliminary results from a prospective, multicenter, pilot study. *Sex Med* 2016;4:e83–e8.
24. Bhat W, Akhtar S, Akali A. Breast augmentation with implants following previous enhancement with Macrolane filler injections. *Aesthet Plast Surg* 2011;35:670–1.
25. Cavallini M, Gazzola R, Metalla M, Vaianti L. The role of hyaluronidase in the treatment of complications from hyaluronic acid dermal fillers. *Aesthet Surg J* 2013;33:1167–74.
26. Gogolewski S, Jovanovic M, Perren SM, Dillon JG, et al. Tissue response and in vivo degradation of selected polyhydroxyacids: polylactides (PLA), poly(3-hydroxybutyrate) (PHB), and poly(3-hydroxybutyrate-co-3-hydroxyvalerate) (PHB/VA). *J Biomed Mater Res* 1993;27:1135–48.
27. Ezzat WH, Keller GS. The use of poly-L-lactic acid filler in facial aesthetics. *Facial Plast Surg* 2011;27:503–9.
28. Jabbar A, Arruda S, Sadick N. Off face usage of poly-L-lactic acid for body rejuvenation. *J Drugs Dermatol* 2017;16:489–94.
29. Smith L, Cockerham K. Hyaluronic acid dermal fillers: can adjunctive lidocaine improve patient satisfaction without decreasing efficacy or duration? *Patient Prefer Adher* 2011;5:133–9.
30. Hexsel DM, Hexsel CL, Iyengar V. Liquid injectable silicone: history, mechanism of action, indications, technique, and complications. *Semin Cutan Med Surg* 2003;22:107–14.
31. Elist JJ, Baniqued M, Hosseini A, Wilson SK. Correction of retractile penis with subcutaneous soft silicone penile implant. *Int J Impot Res* 2020;32:317–22.
32. Naoum C, Dasiou-Plakida D, Pantelidaki K, Dara C, et al. A histological and immunohistochemical study of medical-grade fluid silicone. *Dermatol Surg* 1998;24:867–70.
33. Yanagihara M, Fujii T, Wakamatu N, Ishizaki H, et al. Silicone granuloma on the entry points of acupuncture, venepuncture and surgical needles. *J Cutan Pathol* 2000;27:301–5.
34. Harlim A, Kanoko M, Aisah S. Classification of foreign body reactions due to industrial silicone injection. *Dermatol Surg* 2018;44:1174–82.
35. Requena C, Izquierdo MJ, Navarro M, Martinez A, et al. Adverse reactions to injectable aesthetic microimplants. *Am J Dermatopathol* 2001;23:197–202.
36. Reveillon M, Carre D, Plaquevent M, Alsubaiei F, et al. Severe alveolar haemorrhage related to a silicone embolism syndrome revealed by a chronic penis ulcer: a case report [in French]. *Rev Med Interne* 2016;37:489–92.
37. Sukop A, Heracek J, Mestak O, Borsky J, et al. Penis augmentation by application of silicone material: complications and surgical treatment. *Acta Chir Plast* 2013;55:31–3.
38. Fakin R, Zimmermann S, Jindarak S, Lindenblatt N, et al. Reconstruction of penile shaft defects following silicone injection by bipediced anterior scrotal flap. *J Urol* 2017;197:1166–70.
39. Tsili AC, Xiropotamou ON, Nomikos M, Argyropoulou MI. Silicone-induced penile sclerosing lipogranuloma: magnetic resonance imaging findings. *J Clin Imag Sci* 2016;6:3.
40. Wills S, Byard RW. Lethal silicone embolization syndrome complicating penile, scrotal and breast self-augmentation. *Forensic Sci Med Pathol* 2019;15:304–8.
41. Garcia Diez F, Izquierdo Garcia FM, Beneitez Alvarez ME, Guerreiro Gonzalez R, et al. Penile silicone granuloma [in Spanish]. *Arch Esp Urol* 2005;58:457–60.
42. Plaza T, Lautenschlager S. Penis swelling due to foreign body reaction after injection of silicone. *J Dtsch Dermatol Ges* 2010;8:689–91.